

ONLINE FIRST

Induction of Dermal Collagenesis, Angiogenesis, and Adipogenesis in Human Skin by Injection of Platelet-Rich Fibrin Matrix

Anthony P. Sclafani, MD; Steven A. McCormick, MD

Objective: To evaluate the histological changes induced in human skin by injection of autologous platelet-rich fibrin matrix (PRFM).

Methods: Four healthy adult volunteers were included in the study. Platelet-rich fibrin matrix was prepared from 9 mL of autologous blood using a proprietary system (Selphyl; Aesthetic Factors, Wayne, New Jersey) and injected into the deep dermis and immediate subdermis of the upper arms of subjects. Full-thickness skin biopsy specimens were taken from the treated areas over a 10-week period, and the specimens were processed for histological evaluation.

Results: Findings from histological examination supported the clinical observation of soft-tissue augmentation. As early as 7 days after treatment, activated fibroblasts and new collagen deposition were noted and continued to be evident throughout the course of the study. Development of new blood vessels was noted by 19 days; also at this time, intradermal collections of adipocytes and stimulation of subdermal adipocytes were

noted. These findings became more pronounced over the duration of the study, although the fibroblastic response became much less pronounced. No abnormal mitotic figures were observed at any point, and a very mild chronic inflammatory response was noted only at the earliest time points of the study.

Conclusions: Injection of PRFM into the deep dermis and subdermis of the skin stimulates a number of cellular changes that can be harnessed for use. Coupled with prior *in vitro* and *in vivo* studies, we now have a much clearer picture of the cellular effects of PRFM and its potential uses in facial plastic surgery. Further work is planned to more clearly elucidate the potential role of PRFM in aesthetic and reconstructive surgery.

Trial Registration: clinicaltrials.gov Identifier: NCT00956020

Arch Facial Plast Surg.
Published online October 17, 2011.
doi:10.1001/archfacial.2011.784

Author Affiliations: Division of Facial Plastic Surgery, Department of Otolaryngology (Dr Sclafani), and Department of Pathology (Dr McCormick), The New York Eye and Ear Infirmary, New York; and Department of Otolaryngology, New York Medical College, New York (Dr Sclafani).

SINCE THE TIME OF PARÉ, MODERN surgical care has relied on optimization of local tissue conditions to allow wounds to heal unimpeded. With an improved understanding of the effects of local growth factors, surgeons have begun to manipulate the wound environment to promote more rapid and effective healing. Isolated growth factors have been applied with some success topically (becaplermin for diabetic foot ulcers and palifermin for radiation induced mucositis), but platelet-rich plasma (PRP) has been promoted in the last decade as a more natural and more potent method of manipulating wound healing. However, the process can be time consuming and the results, equivocal.^{1,2}

Platelet-rich fibrin matrix (PRFM) has been used successfully to promote healing of venous leg ulcers³ and in orthope-

dic surgery^{4,5} and has been used clinically in facial plastic surgery since 2009. Several reports⁶⁻¹⁰ have described adding PRFM to autologous fat prior to transfer to enhance fat survival. *In vitro* studies have shown that PRFM can enhance endothelial cell and fibroblast proliferation. One of us (A.P.S.) has reported on the use of PRFM for treatment of deep nasolabial folds (NLFs),¹¹ as well as in other scenarios in a clinical facial plastic surgery practice.^{12,13}

However, the cellular effects of dermal and subdermal injection of PRFM are unclear. In a study evaluating intradermal and subdermal PRFM injection for the treatment of deep NLFs, clinical improvement could be seen as early as 1 week and was statistically significant 2 weeks after treatment. The histological basis for such a rapid clinically apparent change was not immediately evident. This study was de-

signed to evaluate the dermal and subdermal histological changes induced by PRFM.

METHODS

Four healthy adult volunteers were included in the study. Nine-milliliter aliquots of peripheral blood from each subject were placed sterily into 2 collection tubes (Selphyl; Aesthetic Factors, Wayne, New Jersey). Each tube was placed in a centrifuge for 6 minutes at 1100 rpm. The platelets were then resuspended in the supernatant plasma by gently inverting the tube 10 times, and the resulting mixture was transferred sterily to a second tube containing a regulated amount of calcium chloride. This was mixed by gentle inversion, and then 0.5 mL of the mixture was injected into 4 distinct points (at least 15 mm apart from each other) intradermally and subdermally in the skin of each upper arm. At specified time points after treatment between 30 minutes and 10 weeks, 5-mm full-thickness skin biopsy specimens were taken from each injection site and the wounds closed with 3-0 chromic sutures.

Specimen were placed in formalin, sectioned, and stained with hematoxylin-eosin (HE) and trichrome stain (for examination of collagen deposition), periodic acid-Schiff stain (for mucopolysaccharide production) and adipophilin stain (for immunohistochemical evaluation of the presence of adipophilin).

This study was approved by the Institutional Review Board for Human Experimentation at The New York Eye and Ear Infirmary.

RESULTS

Clinically, there was little evidence of inflammation around the treatment sites at any time. The tumescence noted immediately after injection yielded to a palpable fullness of the area at the 1-week follow-up visit, which persisted throughout the duration of the study. At early time points, PRFM induced only a minimal to mild inflammatory response in the dermis, which resolved within 1 week.

Histologically, at 1 week, activated fibroblasts, new collagen deposition, and angiogenesis in the mid- to deep dermis was evident and were accompanied by focal areas of mild lymphocytic infiltrates (**Figure 1**). In addition, the fibrous septae between the subdermal fat became thickened and more cellular. Over time, the inflammatory infiltrates resolved, and dermal changes became more prominent and were accompanied by more obvious angiogenesis. By 3 weeks after injection, there were wide areas of neocollagenesis and angiogenesis (**Figure 2**). Also noted in the dermis was the presence of small, clear cells with eccentric nuclei that resembled adipocytes. Immunohistochemical staining for adipophilin confirmed that these new adipocytes were actively packaging lipid globules. In addition, the more superficial fat cells in the subcutis also were positive for adipophilin, also indicating an anabolic state, while mature adipocytes (including those deeper in the subcutis and thus further from the site of treatment) did not stain positively for adipophilin. At 10 weeks, the fibroblast response appeared less active and fairly quiescent, while new collagen and blood vessels were still evident in the dermis (**Figure 3**). Adipocytes in the dermis and the subdermis were also

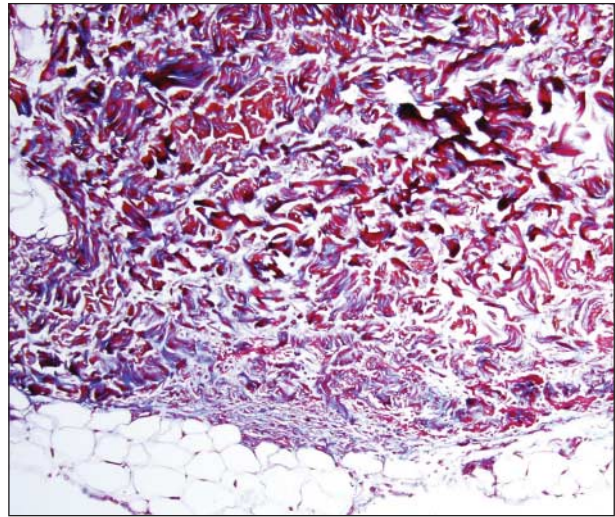


Figure 1. Biopsy at 7 days of skin treated with platelet-rich fibrin matrix. Blue staining is typical of type II collagen (trichrome stain, original magnification $\times 10$).

present and were more uniform in size and stained strongly for adipophilin. No areas of dysplasia were noted in any specimen at any time.

COMMENT

Platelet preparations have been identified as a useful source of autologous growth factors, and many preparations and devices have been promoted for clinical use. However, these various systems differ greatly in their final product. The most commonly studied isolate is PRP, which can differ greatly between systems, chiefly in platelet concentration, red blood cell contamination, white blood cell content, volume, and method of platelet activation. These differences affect the timing of platelet growth factor release, the fibrin substrate on which healing occurs and the degree of associated inflammation. In a study comparing the effects of PRP to autologous blood clot on fibrovascular tissue ingrowth into porous polyethylene implants,² PRP was associated with less neutrophil and macrophage implant infiltration than autologous blood clot at 2 days and significantly more endothelial cells and fibroblasts at 7 days. However, by 14 days and thereafter, no significant cellular differences were noted between autologous blood clot and PRP-treated implants.

Platelet-rich plasma systems can generate a product with an elevated concentration of growth factors up to 80 to 180 times the normal value. However, the optimal concentration of growth factors has not been established; Kakudo et al¹⁴ have described increased adipose-derived stem cell (ADSC) counts and dermal fibroblast proliferation in vitro when grown in the presence of 5% PRP, with growth rates declining in the presence of higher concentrations. Oh et al¹⁵ have shown that transfer of human fat into nude mice underwent less weight and less volume loss over a 10-week period when mixed with activated PRP in a 3.3:1 (fat to PRP) ratio and histologically was more vascularized and demonstrated less vacuolization and fibrosis than fat treated with saline. Clinical

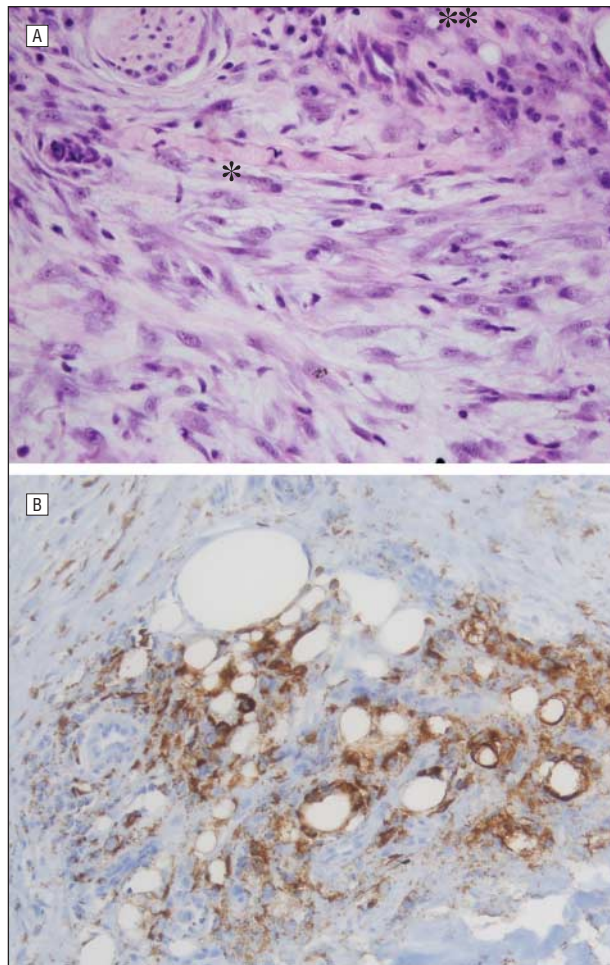


Figure 2. Biopsy at 19 days and immunohistochemical staining. A, Biopsy at 19 days shows reactive fibroblasts, new blood vessel formation (*), and lipid-containing cells (**) (hematoxylin-eosin, original magnification $\times 40$). B, Immunohistochemical staining demonstrates active production of adipophilin, a protein associated with differentiating adipocytes (adipophilin stain, original magnification $\times 20$).

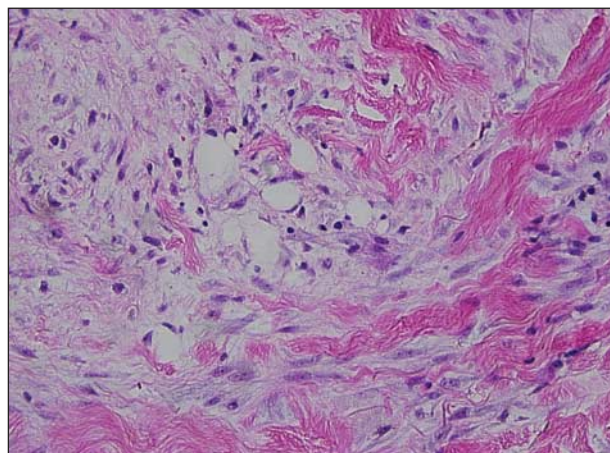


Figure 3. Biopsy at 10 weeks shows less reactive fibroblasts and more mature collagen, blood vessels, and adipocytes in the dermis (hematoxylin-eosin, original magnification $\times 40$).

results with PRP have been equivocal, however, in promoting epithelialization of wounds.^{3,16} On the basis of in vitro results, Kakudo et al¹⁴ have suggested that an es-

sential factor overlooked by standard PRP applications is the need to release platelet growth factors at the appropriate concentrations, pointing out that not only is the effect of PRP concentration dependent, but also that transforming growth factor β , while acting as a mitogen for mesodermal derivatives such as fibroblasts, can inhibit cellular proliferation, especially of cells of ectodermal origin.

An alternative solution has been to isolate platelets and use the plasma as more than a carrier vehicle. Platelet-poor plasma (PPP) has been shown to be mitogenic for mesenchymal and adipose derived stem cells and for adult osteocytes, fibroblasts, endothelial cells, and adipocytes. Kakudo et al¹⁴ have shown that both PRP and PPP, when activated with calcium and thrombin, can induce proliferation in vitro of ADSCs and dermal fibroblasts. The effect of activated PPP potentially may be mediated by the effect of polymerized fibrin. Platelet-rich fibrin matrix captures 60% to 90% of the platelets in a sample of whole blood and allows the platelets to be suspended in almost the entire volume of plasma. This suspension thus harnesses the positive effects of PPP as well as those of platelet-released growth factors. The activation of platelets with calcium chloride induces a more physiologic and more sustained growth factor release from platelets.¹⁷

Anitua et al¹⁷ investigated the effects of application of a plasma rich in growth factors, which is very similar to the PRFM used in our study, with few white blood cells and slightly concentrated platelets in plasma. These workers noted enhanced fibroblast proliferation and secretion of hyaluronic acid from fibroblasts when treated with plasma rich in growth factors and believed the reduction in leukocytes relative to whole blood and PRP reduced the proinflammatory effects of proteases and acid hydrolase released from white blood cells.

Cervelli and coworkers¹⁰ demonstrated that treatment of ADSCs with PRFM increased cellular proliferation at 4, 6, and 8 days but did not increase intracytoplasmic lipid accumulation in these cells.

Platelet-rich fibrin matrix has been used in orthopedic,¹⁸ vascular,³ and oral and maxillofacial surgery¹⁹ in a variety of applications. In each, PRFM has been shown to induce healing through a process of angiogenesis associated with tissue-appropriate cellular proliferation. Bone⁴ as well as soft-tissue regeneration has been induced in both in vitro and in vivo studies. Refractory venous leg ulcers have been successfully treated with topical application of PRFM.³ Clinical use in facial plastic surgery has also been described.¹¹⁻¹³

In vitro studies of PRFM have shown a platelet recovery of 60% to 90%, an average platelet lifespan of 7 days after PRFM formation and sustained release of platelet-derived growth factor, vascular endothelial growth factor, insulinlike growth factor 1, and transforming growth factor β for up to 7 days.^{20,21} Studies have shown that the media from cultures of PRFM increase proliferation of endothelial cells and fibroblasts as well as mesenchymal stem cells.²² There have been several clinical reports of mixing PRFM with autologous fat to enhance the success of cosmetic autologous fat transfer as well as to treat chronic venous leg ulcers,⁶⁻¹⁰ and Torio-Padron et al²³ and

Schoeller et al²⁴ have shown enhanced survival of preadipocytes when coinjected with fibrin.

In a prospective clinical trial,¹¹ PRFM injected into the deep dermis or immediate subdermis produced clinically significant improvement in deep nasolabial folds within 14 days which was sustained throughout the 12 weeks of the study. Since that study, the use of PRFM has been expanded to other indications, including soft-tissue (dermal and subdermal) augmentation for rhytids, folds, depressions, and acne scar effacement and to accelerate wound healing after rhytidectomy, rhinoplasty and autologous fat transfer and around implants.^{12,13} The present study was initiated to better elucidate the mechanism of rapid and sustained volume enhancement after injection of PRFM.

Our early findings corresponded well with our clinical observations, with minimal inflammatory cellular reaction and significant fibroblasts activation and collagen production, correlating well with the lack of clinically apparent inflammation in the presence of visible improvement as early as 7 days after treatment. Angiogenesis was also apparent within the first few weeks of treatment, also in agreement with previous in vitro work. However, the presence of lipid-sequestering cells within the dermis was unexpected, and the association of these cells with activated fibroblasts suggested a common etiology. Immunohistochemical staining for adipophilin was highly positive in these cells at 19 days; adipophilin is a protein found very early in differentiating adipocytes, where it binds and packages cytosolic lipid droplets peripherally.²⁵ It would appear that the adipocytes noted within the dermis represent redifferentiation of existing activated fibroblasts, but less likely, they may be derived from mesenchymal stem cells. In addition, adipocytes in the superficial subcutis also stained positively for adipophilin, indicating an adipose anabolic state.

The process of fibroblast activation and collagen deposition became less prominent after approximately 6 weeks, although adipophilin staining was present throughout the 10 weeks of the study. Despite this, adipogenesis was also much less prominent by the end of the study period, as was angiogenesis. Throughout the course of the study, there was no evidence of granuloma formation, abscess formation, excessive scarring, epidermal hyperplasia or dysplasia.

CONCLUSIONS

In this study we have documented and described the histological changes induced by injections of PRFM into the skin. Platelet-rich fibrin matrix injection leads to development of new blood vessels, activation of fibroblasts with neocollagenesis and adipogenesis within the dermis, and induction of an anabolic state in subcuticular adipocytes. Interestingly, a substantial portion of patients treated clinically with PRFM describe their skin as "softer" after approximately 8 to 12 weeks. It is possible that this description is related to the development of small collections of adipocytes within the dermis. Our findings support the use of PRFM for dermal and subdermal soft-

tissue augmentation in conjunction with surgery (with or without implants) and, in particular, as an adjunct to autologous fat transfer. Acceleration of angiogenesis would, in theory, lead to vascularization of a greater portion of the transplanted fat and yield greater fat retention. In addition, positive staining for adipophilin suggests that existing and induced adipocytes were stimulated into an anabolic state. This, in addition to promotion of rapid revascularization, may be a mechanism for enhancement of adipocyte survival after autologous fat grafting. We are currently investigating the optimal ratio of fat to PRFM in promoting this survival. Angiogenesis, collagen deposition, and adipogenesis appear to be the histologic basis of volume augmentation after PRFM injection in the face.

Accepted for Publication: September 6, 2011.

Published Online: October 17, 2011. doi:10.1001/archfacial.2011.784

Correspondence: Anthony P. Sclafani, MD, Division of Facial Plastic Surgery, Department of Otolaryngology, The New York Eye and Ear Infirmary, 310 E 14th St, Sixth Floor, North Building, New York, NY 10003 (asclafani@nyee.edu).

Author Contributions: Drs Sclafani and McCormick had full access to all of the data in the study and take responsibility for the integrity of the data and the accuracy of the data analysis. *Study concept and design:* Sclafani and McCormick. *Acquisition of data:* McCormick. *Analysis and interpretation of data:* Sclafani and McCormick. *Drafting of the manuscript:* McCormick. *Critical revision of the manuscript for important intellectual content:* Sclafani and McCormick. *Obtained funding:* McCormick. *Administrative, technical, and material support:* Sclafani and McCormick. *Study supervision:* Sclafani and McCormick. **Financial Disclosure:** None reported.

Funding/Support: The costs of this study were underwritten by Aesthetic Factors Inc, Wayne, New Jersey.

REFERENCES

1. Hom DB, Linzie BM, Huang TC. The healing effects of autologous platelet gel on acute human skin wounds. *Arch Facial Plast Surg.* 2007;9(3):174-183.
2. Sclafani AP, Romo TR III, Ukrainsky G, et al. Modulation of wound response and soft tissue ingrowth in synthetic and allogeneic implants with platelet concentrate. *Arch Facial Plast Surg.* 2005;7(3):163-169.
3. O'Connell SM, Impeduglia T, Hessler K, Wang XJ, Carroll RJ, Dardik H. Autologous platelet-rich fibrin matrix as cell therapy in the healing of chronic lower-extremity ulcers. *Wound Repair Regen.* 2008;16(6):749-756.
4. Gamradt SC, Rodeo SA, Warren RF. Platelet rich plasma in rotator cuff repair. *Tech Orthop.* 2007;22(1):26.
5. Sanchez M, Azofra J, Aizpurua B, et al. Application of growth factor-rich autologous plasma in arthroscopic surgery. *Cuadernos de Arthroscopia.* 2003;10:12-19.
6. Azzena B, Mazzoleni F, Abatangelo G, Zavan B, Vindigni V. Autologous platelet-rich plasma as an adipocyte in vivo delivery system: case report. *Aesthetic Plast Surg.* 2008;32(1):155-161.
7. Cervelli V, Gentile P, Grimaldi M. Regenerative surgery: use of fat grafting combined with platelet-rich plasma for chronic lower-extremity ulcers. *Aesthetic Plast Surg.* 2009;33(3):340-345.
8. Cervelli V, Palla L, Pascale M, De Angelis B, Curcio BC, Gentile P. Autologous platelet-rich plasma mixed with purified fat graft in aesthetic plastic surgery. *Aesthetic Plast Surg.* 2009;33(5):716-721.
9. Cervelli V, Gentile P. Use of cell fat mixed with platelet gel in progressive hemifacial atrophy. *Aesthetic Plast Surg.* 2009;33(1):22-27.
10. Cervelli V, Gentile P, Scioli MG, et al. Application of platelet-rich plasma in plas-

- tic surgery: clinical and in vitro evaluation. *Tissue Eng Part C Methods*. 2009; 15:1-9.
11. Sclafani AP. Platelet-rich fibrin matrix for improvement of deep nasolabial folds. *J Cosmet Dermatol*. 2010;9(1):66-71.
 12. Sclafani AP. Applications of platelet-rich fibrin matrix in facial plastic surgery. *Facial Plast Surg*. 2009;25(4):270-276.
 13. Sclafani AP. Safety, efficacy, and utility of platelet-rich fibrin matrix in facial plastic surgery [published online February 21, 2011]. *Arch Facial Plast Surg*. 2011; 13(4):247-251.
 14. Kakudo N, Minakata T, Mitsui T, Kushida S, Notodihardjo FZ, Kusumoto K. Proliferation-promoting effect of platelet-rich plasma on human adipose-derived stem cells and human dermal fibroblasts. *Plast Reconstr Surg*. 2008; 122(5):1352-1360.
 15. Oh DS, Cheon YW, Jeon YR, Lew DH. Activated platelet-rich plasma improves fat graft survival in nude mice: a pilot study. *Dermatol Surg*. 2011;37(5):619-625.
 16. Danielsen P, Jørgensen B, Karlsmark T, Jørgensen LN, Agren MS. Effect of topical autologous platelet-rich fibrin versus no intervention on epithelialization of donor sites and meshed split-thickness skin autografts: a randomized clinical trial. *Plast Reconstr Surg*. 2008;122(5):1431-1440.
 17. Anitua E, Sánchez M, Zalduendo MM, et al. Fibroblastic response to treatment with different preparations rich in growth factors. *Cell Prolif*. 2009;42(2):162-170.
 18. Sánchez M, Anitua E, Azofra J, Andía I, Padilla S, Mujika I. Comparison of surgically repaired Achilles tendon tears using platelet-rich fibrin matrices. *Am J Sports Med*. 2007;35(2):245-251.
 19. Simon BI, Gupta P, Tajbakhsh S. Quantitative evaluation of extraction socket healing following the use of autologous platelet-rich fibrin matrix in humans. *Int J Periodontics Restorative Dent*. 2011;31(3):285-295.
 20. Carroll RJ, Arnoczky SP, Graham S, O'Connell SM. *Characterization of Autologous Growth Factors in Cascade Platelet-Rich Fibrin Matrix (PRFM)*. Edison, NJ: Musculoskeletal Transplant Foundation; 2005. Publication No. 128-XM 307C5.
 21. O'Connell SM, Carroll RJ, Beavis A, Arnoczky SP. *Flow Cytometric Characterization of Cascade Platelet-Rich Fibrin Matrix (PRFM): The Impact of Exogenous Thrombin of Platelet Concentrates (PC)*. Edison, NJ: Musculoskeletal Transplant Foundation; 2006.
 22. Lucarelli E, Beretta R, Dozza B, et al. A recently developed bifacial platelet-rich fibrin matrix. *Eur Cell Mater*. 2010;20:13-23.
 23. Torio-Padron N, Baerlecken N, Momeni A, Stark GB, Borges J. Engineering of adipose tissue by injection of human preadipocytes in fibrin. *Aesthetic Plast Surg*. 2007;31(3):285-293.
 24. Schoeller T, Lille S, Wechselberger G, Otto A, Mowlavi A, Piza-Katzer H. Histomorphologic and volumetric analysis of implanted autologous preadipocyte cultures suspended in fibrin glue: a potential new source for tissue augmentation. *Aesthetic Plast Surg*. 2001;25(1):57-63.
 25. Wolins NE, Quaynor BK, Skinner JR, Schoenfish MJ, Tzekov A, Bickel PE. S3-12, adipophilin, and TIP47 package lipid in adipocytes. *J Biol Chem*. 2005; 280(19):19146-19155.